



DOI: 10.31146/1682-8658-ecg-172-12-87-89

Management of villous adenoma — beyond endoscopic techniques*

B. Sisir; S. Sankar, Jagan Balu, Santhosh Kumar G., M.N.V. Neelendra

Sri Ramachandra Institute of Higher Education & Research (Deemed to be University), Porur, Chennai, India

Лечение ворсинчатой аденомы неэндоскопическими методами*

Б. Сисир, С. Санкар, Джаган Балу, Сантош Кумар Г., М.Н.В. Нилendra

For citation: Sisir B.; Sankar S., Balu Jagan, Santhosh Kumar G., Neelendra M.N.V. Management of villous adenoma — beyond endoscopic techniques. *Experimental and Clinical Gastroenterology*. 2019;172(12): 87–89. DOI: 10.31146/1682-8658-ecg-172-12-87-89

Для цитирования: Б. Сисир, С. Санкар, Джаган Балу, Сантош Кумар Г., М.Н.В. Нилendra Лечение ворсинчатой аденомы неэндоскопическими методами. *Экспериментальная и клиническая гастроэнтерология*. 2019;172(12): 87–89. DOI: 10.31146/1682-8658-ecg-172-12-87-89

Dr. B. Sisir — Pg(Mch) department of Surgical Gastroenterology Sri Ramachandra Institute of Higher Education and Research

Dr. S. Sankar — Professor, Head of Department of SGE, Sri Ramachandra Institute of Higher Education and research

Dr. Jagan Balu — Assistant professor, Department of SGE Sri Ramachandra Institute of Higher Education and Research

Dr. Santhosh Kumar G. — Pg (Mch) department of SGE Sri Ramachandra Institute of Higher Education and Research

Dr. M.N.V. Neelendra — Pg (Mch) department of SGE Sri Ramachandra Institute of Higher Education and Research

Б. Сисир – отделение хирургической гастроэнтерологии Института высшего образования и исследований Шри Рамачандры

С. Санкар – профессор, заведующий кафедрой SGE, Институт высшего образования и исследований Шри Рамачандры

Джаган Балу – доцент кафедры хирургической гастроэнтерологии

Сантош Кумар Г. – кафедра хирургической гастроэнтерологии

М.Н.В. Нилendra – кафедра хирургической гастроэнтерологии

✉ **Corresponding author:**

Dr. B. Sisir

sisir_jade@outlook.com

romeosignor@gmail.com

Summary

Polyp' is a descriptive term for abnormal projection above an epithelial surface and is not a histological diagnosis. Adenoma is a benign neoplasm of glandular origin and is significant because they are cancers in making. Once a polyp is found, it must be removed in total. Attempts at estimating the polyp histology by endoscopic appearance are often incorrect. With recent advances in endoscopic techniques, most of the polyps are removable through endoscopy. However, there remain a few situations depending on location, size of the lesion and endoscopic expertise available, where complete removal of the polyp requires surgical intervention especially so for large sessile adenomas. We are presenting here four cases of villous adenoma requiring surgical intervention each managed differently depending on presentation and overall clinical picture.

* Illustrations to the article are on the colored inset of the Journal.

* Иллюстрации к статье – на цветной вклейке в журнал.

Резюме

Термин «полип» является собирательным и не обозначает какие-либо гистологические изменения, обнаруживаемые в разросшейся и выступающей над поверхностью слизистой оболочки ткани. Современные эндоскопические технологии позволяют достаточно легко удалить это большей частью доброкачественное, но зачастую склонное к малигнизации новообразование. Вместе с тем, величина новообразования и его локализация не всегда позволяют использовать эндоскопические технологии, поэтому мы приводим четыре различных наблюдения, когда пришлось прибегнуть к хирургическим методам вмешательства.

Introduction

The word 'polyp' is a descriptive term for any abnormal projection above an epithelial surface [1]. Tissues present in the colon appear as a polyp in histological analysis including fat (lipoma), muscle (leiomyoma), nerve (ganglioneuroma, schwannoma), fibrous tissue (fibroma) etc. Serrated polyps, adenomatous polyps and hamartomatous polyps are three most common and type of polyps found in the large intestine and arising from an overgrowth of epithelium [1, 2].

Adenomas are the most common neoplasms of colon and rectum; they are benign of glandular origin, and as per study 90% of such cases develop from preexisting adenomatous polyps.¹. Adenocarcinoma is the most common cancer of colon and rectum arises from an adenoma. Thus adenomas are significant because they are cancers in making [3]; having access to these precursor lesions containing dysplasia there is an opportunity to prevent cancer by removing them. Therefore,

polypectomy often leads to a momentous reduction in the incidence of adenomas [4]. The genetic basis of adenomas and their progression to invasive carcinomas has been explained by Vogelstein in his famous vogelgram², which has been validated and labeled as chromosomal instability mechanism for the advance of colorectal cancer [5]. Though, an endoscopic procedure is the first line of treatment for the villous tumor, some time the size and the location restrict the use of endoscopic removal. Therefore, radical surgery and/or minimally invasive surgery are the choice of treatment.

With advancements in endoscopic techniques, most adenomatous lesions are amenable to complete removal by endoscopy. However, those that do not require surgical intervention for complete removal. We are presenting here three cases of colorectal adenomas that required surgical interventions of varying radicality depending on lesion location and extent.

Case 1

A 50-year-old male with a chief complaint of altered bowel habits was evaluated in a local hospital. Colonoscopy was done twice, a sessile polyp of size 2,5 cm was found in the upper rectum.

The polyp was biopsied but not removed completely. He was later referred to our department.

Trans Anal Minimal Invasive Surgery (TAMIS) was done using a SILS port placed trans anally.

The lesion was removed in total and HPE was reported as a villous adenoma with low-grade dysplasia.

Case 2

A 65-year-old male with chief complaints of constipation and mucus discharge per rectum was evaluated in a hospital, colonoscopy was done which showed a large sessile polyp in the sigmoid colon. Piece meal polypectomy was done and biopsy was reported as a tubule-villous adenoma with low-grade dysplasia. He presented to

us one year later with similar complaints. Colonoscopy revealed a large polypoid lesion in sigmoid not amenable to endoscopic removal. Colonoscopic tattooing was done to aid in intra op identification. Laparoscopy-assisted segmental resection was done. HPE reported as a tubulovillous adenoma with high-grade dysplasia.

Case 3

A 70-year-old male with a primary complaint of altered bowel habits, mucus discharge per rectum and hypokalemia on biochemical evaluation. The endoscopic evaluation showed a large wide-based sessile polyp in the mid and

lower rectum. In view of the large size of the lesion complete removal through endoscopy was not possible and was referred to us. Anterior resection was performed and biopsy was reported as an adenoma with high grade dysplasia.

Case 4

A 57-year-old male with a primary complaint of bleeding and mucus discharge per rectum was evaluated at a local hospital in 2007. Colonoscopy showed a large sessile polyp 8cm from anal verge which was biopsied (not excised). The biopsy was reported as a tubule-villous adenoma with low-grade dysplasia. No further intervention was done at that point in time. Three years later in 2010 he had similar complaints and was evaluated at a special centre where colonoscopy was done and a large sessile broad-based polyp was found in the rectum, piece meal polypectomy was done.

6 years later he presents to us with complaints of bleeding per rectum and a history of loss of weight and loss of appetite. Colonoscopy and CECT showed circumferential long segment proliferative growth starting 4 cm from anal verge. Biopsy from the lesion showed TV adenoma with low-grade dysplasia in the proximal rectum and high-grade dysplasia in distal rectum. Intra operatively the lesion was found to be extending distally upto 2cm from the anal verge. Abdomino perineal resection (APR) was done and the final biopsy was reported as invasive mucinous adenocarcinoma pT3N2bM0 low grade well differentiated.

Discussion

Most of the polyps are asymptomatic. Bleeding, mucus discharge, altered bowel habits and abdominal pain are the most common symptoms when they are symptomatic. Endoscopy is diagnostic and therapeutic. Majority of the polyps can be excised by endoscopic techniques.

A simple endoscopic polypectomy through snaring has low risk of complications, bleeding is the most common complication; perforation rate is less than 2%. ESD and EMR procedures carry the risk of perforation (5%). Comparatively surgery in any form has higher

morbidity rates and risk of attending complications but is essential in selected cases.

In our study in the first case patient had a sessile polyp in upper rectum tackled by transanal minimal invasive surgery through SILS port. In the second case, it was large sessile T-V adenoma removed by lap assisted segmental resection. In third case patient had broad base sessile polyp in mid rectum requiring anterior resection and in fourth case patient had a long-standing T-V adenoma with malignant transformation which was removed by APR.

Pedunculated polyps and small sessile polyps are mostly amenable to endoscopic removal. Large sessile polyps and flat adenomas are difficult to remove

endoscopically but can be done through endoscopic submucosal dissection and piecemeal polypectomy. Those that cannot be removed completely by endoscopic techniques should be addressed surgically. Attempts at estimating polyp histology by endoscopic appearance are often incorrect [9, 10]. It is reasonable to leave polyps untreated if they are typical hyperplastic polyps occurring in clusters in the rectum and sigmoid in which case they should be sampled to confirm the histological diagnosis. Otherwise, every individual polyp should be removed. In case of large villous tumors, total removal of tumours in a single piece is required, that because it has tendency to reappear with possible malignant degeneration of residual lesion.

References | Литература

1. Burnstein MJ, Hicks TC. Polyps. In: The ASCRS Textbook of Colon and Rectal Surgery 2007 (pp. 362–372). Springer, New York, NY.
2. Jass JR. Gastrointestinal polyposis: clinical, pathological and molecular features. *Gastroenterology Clinics of North America*. 2007 Dec 1;36(4):927–46.
3. Law WL, Chu KW. Impact of total mesorectal excision on the results of surgery of distal rectal cancer. *British journal of surgery*. 2001 Dec;88(12):1607–12.
4. Kedia P, Waye JD. Colon polypectomy: a review of routine and advanced techniques. *Journal of clinical gastroenterology*. 2013 Sep 1;47(8):657–65.
5. Vogelstein B, Fearon ER, Hamilton SR, Kern SE, Preisinger AC, Leppert M, Smits AM, Bos JL. Genetic alterations during colorectal-tumor development. *New England Journal of Medicine*. 1988 Sep 1;319(9):525–32.
6. Jarnum S, Jensen H. Diffuse gastrointestinal polyposis with ectodermal changes: a case with severe malabsorption and enteric loss of plasma proteins and electrolytes. *Gastroenterology*. 1966 Jan 1;50(1):107–18.
7. Walsh RM, Ackroyd FW, Shellito PC. Endoscopic resection of large sessile colorectal polyps. *Gastrointestinal endoscopy*. 1992 May 1;38(3):303–9.
8. Middleton PF, Sutherland LM, Maddern GJ. Transanal endoscopic microsurgery: a systematic review. *Diseases of the colon & rectum*. 2005 Feb 1;48(2):270–84.
9. Chapuis PH, Dent OF, Goulston KJ. Clinical accuracy in diagnosis of small polyps using flexible fiberoptic sigmoidoscope. *Dis Colon Rectum*. 1982;25(7):669–672.
10. Norfleet RG, Ryan ME, Wyman JB. Adenomatous and hyperplastic polyps cannot be reliably distinguished by their appearance through fiberoptic sigmoidoscope. *Dig Dis Sci*. 1988;33(9):1175–1177.

К статье

Management of villous adenoma — beyond endoscopic techniques (стр. 87–89)

To article

Лечение ворсинчатой аденомы неэндоскопическими методами (р. 87–89)

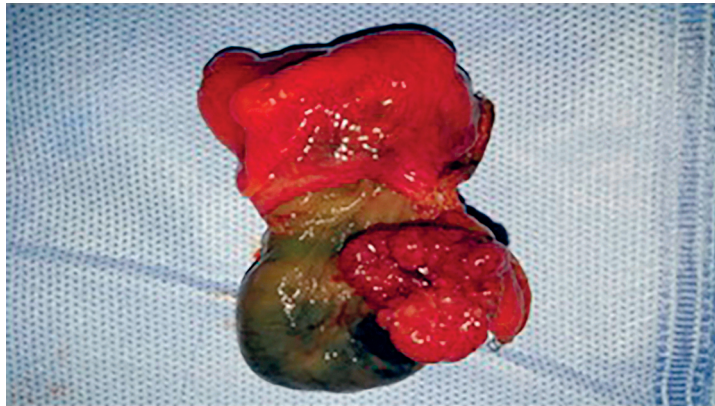


Figure 1.

Рисунок 1.

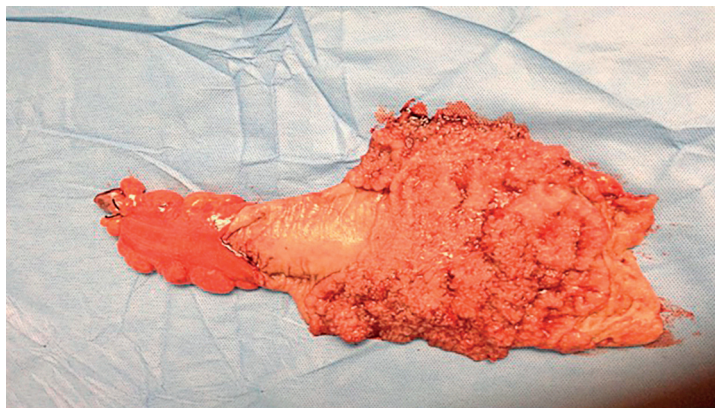


Figure 2.

Рисунок 2.

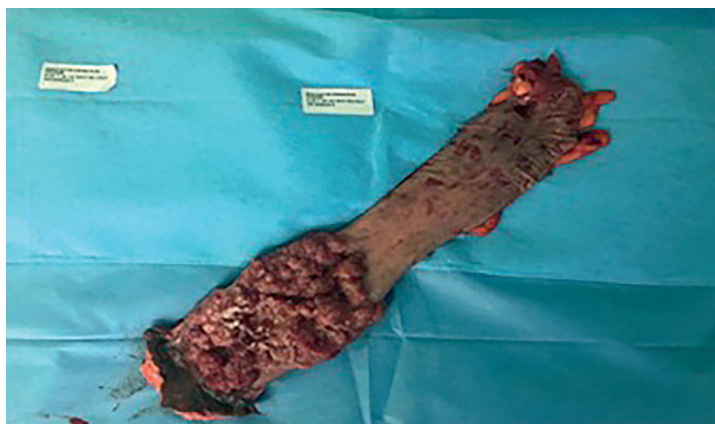

Figure 3.

Рисунок 3.